HNO 2012
DOI 10.1007/s00106-012-2573-3

S. Schröder, U. Reineke, M. Lehmann, J. Ebmeyer, H. Sudhoff

Clinic for Otorhinolaryngology, Head and Neck Surgery, Bielefeld Clinics, Bielefeld, Germany

Chronic obstructive eustachian tube dysfunction in adults

Long-term results of balloon dilatation eustachian tuboplasty

A large number of patients have chronic obstructive eustachian tube dysfunction, which may, among other things, lead to chronic otitis media. The prevalence of chronic tube ventilation disorders is about 1% of the adult population. Forty per cent of the children up to the age of 10 develop at least a temporary functional disorder of the eustachian tube.[3] Classic symptoms are a feeling of pressure on the ears, which is increased during flying and/or riding up- or downhill, and the inability to perform the Valsalva manoeuvre. The authors in medical literature agree that persistent dysfunction of the eustachian tube may, among other things, lead to middle ear effusion and chronic otitis media up to atelektasis and cholesteatoma. Many studies in both children and adults have shown that a markedly increased prevalence of obstructive tubal ventilation disorders was present in up to 70% of patients undergoing tympanoplasty due to chronic otitis media or cholesteatoma surgery.[2, 24] Therefore, not only Pau et al emphasise the importance of good ventilation of the middle ear for postoperative progress and the outcome of tympanoplasty.[4, 17]

Good diagnostic tools and conservative and effective therapy options for chronic obstructive eustachian tube dysfunction have been lacking so far.[23]

Determination of the topographic location of the eustachian tube within the skull relative to e.g. the arteria carotis interna as well as its exact structure is essential for diagnostics and therapy of dysfunctions of the tuba auditiva. The length of the auditory tube between the tubal opening in the nasal pharynx (ostium pharyngeum) and the tympanic aperture in the middle ear (ostium tympanicum) is about 31–38mm in adults. It consists of an osseous part (pars ossea) and a cartilaginous membrane part (pars cartilaginea), which accounts for 2/3 of its length beginning at the epipharynx.[9, 12]

Currently, ear microscopy with the Valsalva manoeuvre, pneumatic otoscopy, and the Toynbee experiment are available as simple and feasible methods for diagnosing disorders of the tuba eustachii. In addition, there are some diagnostic measures requiring much higher effort, while partly yielding only a minimally higher degree of useful information. Impedancemetry in the pressure room is very laborious, but offers only indirect information on the tubal function and can be performed only if the eardrum is intact. As an alternative, the aspiration-deflation test and the inflation-deflation test shall be mentioned. The most meaningful test seems to be the SITV test (swallow-insufflate-Toynbee-Valsalva test), even if it has not become widely used in daily clinical practice. A current paper elaborates on the depiction of the tubal function using magnetic resonance imaging (MRI).[10] Moreover, research is going on to optimise fibre optic mini-endoscopes for direct endoluminal depiction of the eustachian tube, as well as with regard to sonography of the eustachian tube.[16, 18] A newer kind of diagnostics of tubal ventilation disorders with intact or perforated tympanic membrane which is suitable for clinical practice is modified tubomanometry (TMM) acc. to Estève, which shall be described in more detail below.[5, 6]

Various other therapeutic approaches for treating chronic obstructive tubal ventilation disorders have been tested. Established methods for symptomatic treatment of chronic tubal ventilation disorders and their sequelae are paracentesis and drainage of the middle ear. Further, possible options of bougienage of the eustachian tube, drainage (e.g. using silicon pipes or tubal wires made of gold), or laser tuboplasty have been reviewed.[1, 9, 14, 18]

Balloon dilatation of the eustachian tube (balloon dilatation eustachian tuboplasty) via the nasopharyngeal tubal ostium is a new therapeutic approach.

This procedure for treating chronic obstructive tubal ventilation disorders using the Bielefeld balloon catheter has been clinically applied for the first time in February 2009 after performing numerous preliminary examinations. In this paper, we would like to report on the long-term results of this new treatment and describe the experiences made so far.

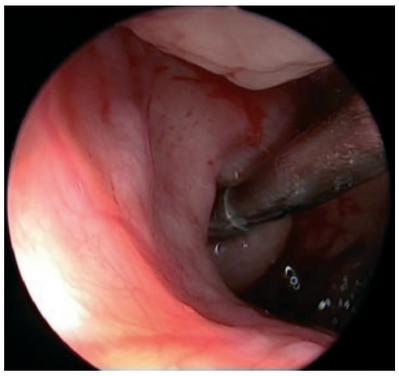

Fig. 1 ▲ Dilatation of the eustachian tube using the Bielefeld balloon catheter

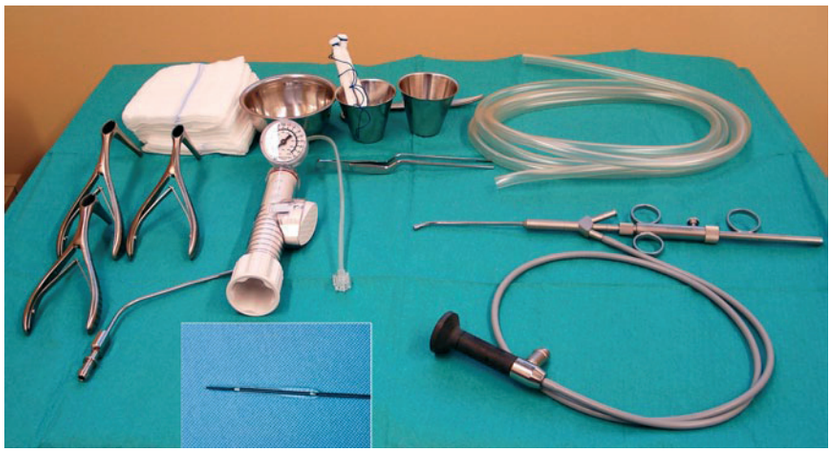

Fig. 2 ▲ Instruments and catheter tip

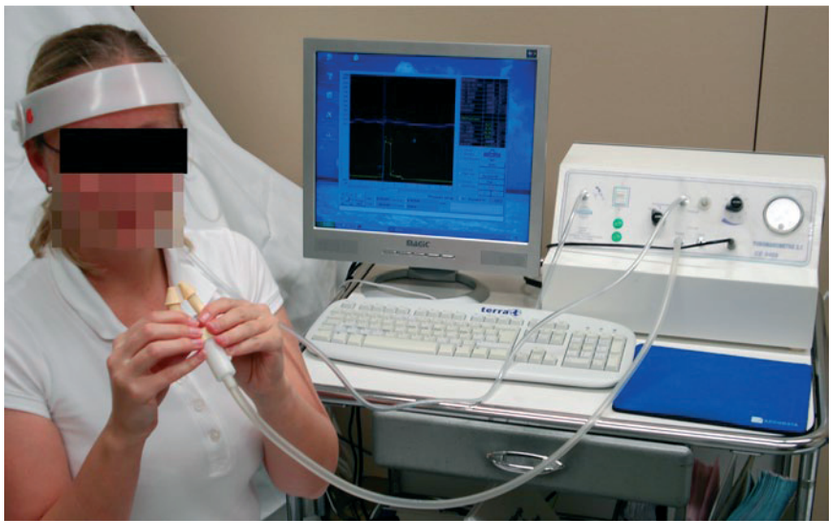

Fig. 3 ▲ Measurement unit for tubomanometry

Patients and methods

Balloon dilatation eustachian tuboplasty, which has been developed at Bielefeld, is carried out transnasal-endoscopically via the pharyngeal tubal ostium using a balloon catheter under general anaesthesia. This procedure shall enhance the function of the tuba auditiva in case of chronic obstructive eustachian tube dysfunction. For diagnostic purposes and as a preliminary examination, each patient is subjected to a clinical examination, audiometry, tympanometry, TMM, and computer tomography (CT) of the petrosal bones. To assess the pre- and post-operative tubal function, the Bielefeld tube score has been used. A follow-up assessment of the symptoms and findings of the patients treated is performed 1 week, 2 weeks, 2 months, and 12 months after tube dilatation.

In the period between February 2009 and August 2011, we carried out balloon dilatation eustachian tuboplasty using the Bielefeld balloon catheter in a total of 120 patients (209 cases). The study included patients with a clinically ascertained chronic obstructive eustachian tube dysfunction who had given written informed consent. Exclusion criteria were an age under 18 years, a pre-operatively non-identifiable nasopharyngeal fold, an arteria carotis interna lacking bone cover, and a distinct septum deviation and hyperplasia of the nasal concha. We examined the subjective satisfaction of these patients with the surgical outcome, possible complications, and the development of the findings using the tube score. Prior to and after the operation, we compared both the tube score and the ability to perform the Valsalva manoeuvre as well as the values measured by TMM acc. to Estève.

Here,

- a "distinct improvement" is the increase of the tube score by more than 2 points,
- a "slight improvement" is the increase of the tube score by 1–2 points, and
- "no improvement" is a tube score which is identical to or worse than the pre-operative values.

The data were entered in an Excel data base and evaluated using SPSS 15.00 (Armank, NY, USA). As the values of the tube score do not show normal distribution in the Kolmogorov-Smirnov test ($p<0.05$), a non-parametric test procedure for dependent features was used in the follow-up visits to describe the development of the tube score (Wilcoxon test and Friedman test, resp.).

Balloon dilatation eustachian tuboplasty

Balloon dilatation of the eustachian tube is a surgical procedure to treat chronic obstructive eustachian tube dysfunction. Under a short anaesthesia, the fibre optic endoscope is positioned through the nose in front of the nasopharyngeal fold in the epipharynx. As an alternative, a rigid 45° Hopkins scope can be used in the inferior nasal meatus for visual control (Fig. 1). The balloon with a defined length of 2cm is placed in the cartilaginous part of the tuba auditiva and pumped up using physiological sodium chloride solution to a pressure of 10bar for 2 minutes (Fig. 2). This may lead to microfractures in the cartilage with persistent dilatation of the so-called Rüdinger safety canal.[13]

Abstract

HNO 2012 · [jvn]:[afp]–[alp] DOI 10.1007/s00106-012-2573-3

S. Schröder · U. Reineke · M. Lehmann · J. Ebmeyer · H. Sudhoff

Chronic obstructive eustachian tube dysfunction in adults. Long-term results of balloon dilatation eustachian tuboplasty

Background. Sufficient diagnostic tools and effective therapies for chronic obstructive eustachian tube dysfunction are lacking.
Patients and methods. A total of 120 patients (209 ears) with chronic obstructive eustachian tube dysfunction were treated over a 2-year period using transnasal endoscopic balloon dilatation of the cartilaginous part of the eustachian tube (balloon dilatation eustachian tuboplasty, BET). A balloon catheter is inserted into the eustachian tube via the pharyngeal opening and dilated with a pressure of 10bar for 2 minutes.
Results. The first 12 patients (20 dilatations) had a pretreatment average tube score of 1.25 (±1.83 SD), and 1 year after treatment, the score improved to 6.2 (±2.61 SD). Furthermore, the pretreatment and 2-month posttreatment data of 66 additional patients (115 dilatations) were analysed. In these patients, the tube score improved significantly from 2.21 (±2.02 SD) to 5.4 (±2.53 SD).
Conclusion. The initial long-term results suggest that BET is feasible and safe for the treatment of chronic obstructive eustachian tube dysfunction.

Keywords
Balloon dilatation eustachian tuboplasty · Eustachian tube · Tuba auditiva · Balloon dilatation · Tube score

Tubomanometry

The principle of TMM acc. to Estève consists in a controlled application of pressure in the nose to determine the latency between the pressure application and the opening of the fibrocartilage part of the eustachian tube (Fig. 3).
A calibrated positive pressure generator is connected to the patient's nose in an airtight way using a pipe and a double-ended nostril adapter. The generator allows the application of controlled positive pressures in the range of 15–60mbar. As a rule, we use 30, 40 and 50mbar for measuring – which corresponds to a change in air pressure when ascending or descending 300, 400, and 500 metres, resp. The second pressure measuring probe is located within a pipe which is used to seal the external acoustic meatus airtight. It registers the pressure change caused by the eardrum movement during pressure equalisation. The corresponding pressure curves are shown on the monitor, and various measuring values are calculated. For assessment, we primarily use the opening latency index (R value) as essential parameter (Fig. 4). This index reflects the time between pressure application in the nasopharynx and measurement of a pressure change in the acoustic meatus.[13, 21] From the medical history and the TMM results, we calculate the tube score as a quantitative instrument for assessing a possible indication for surgery and comparability. The tube score consists of the ability to perform the Valsalva manoevre (yes / sometimes / no – corresponding to 2 / 1 / 0 points), the possibility of equalising the pressure through swallowing (yes / sometimes / no – corresponding to 2 / 1 / 0 points), and the R value during TMM with 30, 40, 50mbar (≤1 / >1 / no R value or no tube opening – corresponding to 2 / 1 / 0 points). In total, the tube score can assume values from 0–10 points. A score of 10 corresponds to optimum eustachian tube function, and a score of 0 reflects a strongly obstructive eustachian tube dysfunction (Tbl. 1).

Diagnostics and Therapy

In general, the patients initially present during our consultation hours for dysfunction of the tuba auditiva. In the scope of this consultation, the patient's medical history is discussed in detail, focussing on the ears and nose. Important key questions refer to previous surgeries at the ears, nose or throat, restrictions to breathing through the nose, rhinorrhoea, feeling of pressure in the ears, e.g. during air travel or when riding up- or downhill, ability to equalise the pressure, and previous treatment attempts. An otorhinolaryngological examination follows, with emphasis on the epipharynx and the ears using the Politzer and Valsalva manoeuvres.
Further, tympanometry, audiometry, and TMM for determining the tube score are performed. Depending on the findings and as of a tube score of ≤5, as a rule, we offer the patients to have a tube dilatation performed, with a corresponding recording of the medical history and clinical information. This means that the patients report to not be able to perform pressure equalisa-

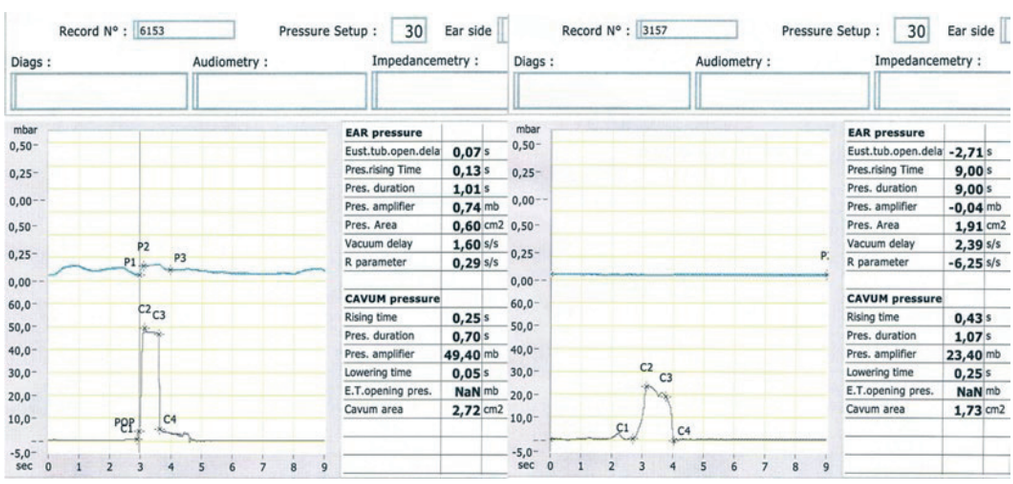

Fig. 4 ◄ Tubomanometry results for normal eustachian tube function (R<1) to the *left*, and tubomanometry results for no tube opening (R not measurable) to the *right*

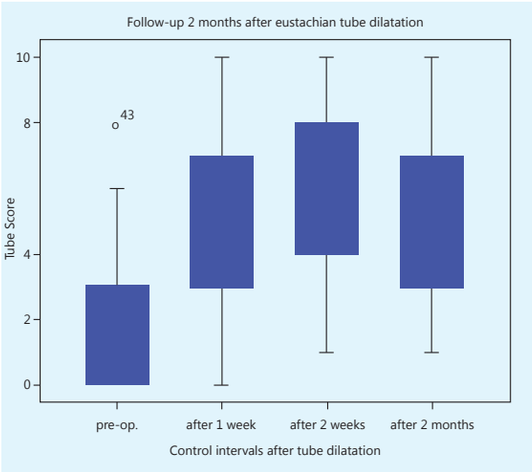

Fig. 5 ◄ Postoperative development of the tube score (115 ear findings). *Bar*: median; *box*: bottom and top quartiles; *block*: range without outliers

Fig. 6 ► Postoperative development of the tube score (20 ear findings). *Bar*: median; *box*: bottom and top quartiles; *block*: range without outliers

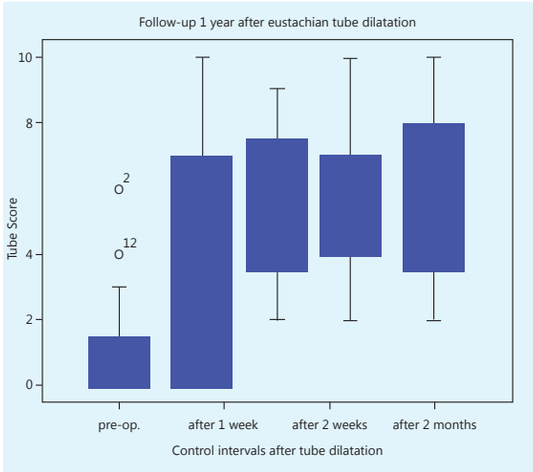

tion and to have a bothering feeling of pressure on the ear concerned when overcoming greater height differences. Moreover, the TMM results must show no or only a very small opening of the eustachian tube. As a rule, this corresponds to a tube score of ≤5. With patients in which the diagnosis of chronic obstructive eustachian tube dysfunction cannot be ascertained, a control assessment on an outpatient basis is performed 2 months after the initial consultation to further evaluate the findings.

The inpatient stay for balloon dilatation eustachian tuboplasty is 3 days on an average. On the day of admission, the routine admission assessment with otorhinolaryngological status, medical history, and preliminary examination for anaesthesia is performed. In addition, we carry out current tympanometry, audiometry, and TMM. Prior to each tuboplasty, high-resolution CT of the petrosal bones is performed in order to, among other things, determine the location of the eustachian tube within the skull relative to the arteria carotis interna and its bone cover. On the following day, the operation is carried out under brief general anaesthesia. We prescribe ciprofloxacin 2x500mg p.o. as antibiotic prophylaxis for 5 days, nasal spray containing xylometazoline / dexpanthenol 3 times a day, and 1x1 hub of nasal spray containing cortisone for 2 months to reduce the swelling in the nasal mucosa. Follow-up visits to our special consultation hours 1 week, 2 weeks, 2 months, and 1 year after the operation are scheduled. At these visits, we ask the patients about their symptom development, perform a otorhinolaryngological examination focussing on the ears and a TMM. The pathological audiogram recorded during the preliminary assessment is reviewed.

Results

At the Clinic for Otorhinolaryngology, Head and Neck Surgery of the Bielefeld Clinics, a total of 120 patients were treated using balloon dilatation eustachian tuboplasty, i.e. the tuba auditiva was dilated in 209 cases, until August 2011. The first balloon dilatation of the eustachian tube using the Bielefeld balloon catheter had been performed in February 2009.
The procedure has proven unproblematic when applied by a surgeon and an assistant. It has been demonstrated that the intervention can also be carried out under anticoagulation with ASA, clopidogrel or even cumarines, but increased bleeding of the mucosa can impede the intraoperative view here. Anatomic circumstances such as distinct septal deviations or septal spurs can also make the intervention more difficult, but have never been the cause for a breakup of surgery so far. In one of the patients we treated, massive bilaterial scarring of the tubal ostium after conchotomy more than 20 years ago became obvious only during the operation so that a dilatation of the eustachian tube could not be performed. Regarding the course of the procedure, it seems more practical now in many cases to use the endoscope as an aid to insert the catheter and visualise the placement of the endoscope and the dilatation process by means of a separate flexible or rigid fibre optic scope.
There have been no significant complications when applying the procedure. With 2 patients, the existing tinnitus was felt to be louder for about 2 weeks, and with some patients, slight bleeding occurred in the area of the nasal mucosa and the epipharynx mucosa, which did not require any special treatment. Post-operatively and during follow-up, a gaping eustachian tube has never occurred.
In total, the patients did not report any pain or other impediments on the first day after the operation. Only with about 20% of the 120 patients, there was a subjective improvement of the symptoms already on the day of discharge.

In the patients‘ self-assessment of symptom improvement, the results after 2 months were significantly better than in the first two weeks after surgery, which was also confirmed by the TMM results. With 24 of the 115 ears treated and followed-up, there was no material improvement of the symptoms and findings at 2 months after the operation. This corresponds to about 21% of the ears treated. In summary, we can conclude that we were able to reduce the underlying symptoms and did achieve a measurable improvement of the eustachian tube function in about 80% of the 66 patients followed-up at about 2 months after surgery. 60% of the cases showed a distinct improvement combined with the ability to perform the Valsalva manoevre, a tube score of at least 5, and a tube score improved by at least 3 points. In some cases, improvement of the audiological findings was achieved as well. The follow-up assessments at 12 months after the operation have shown even better results, with a distinct improvement of the symptoms and findings in 90% of the – however

Tbl. 1 Calculation of the tube score

Symptom / finding	2 points	1 point	0 points
Clicking noise when swallowing	Yes, always	Sometimes	No, never
Positive Valsalva manoeuvre	Yes, always	Sometimes	No, never
TMM 30mbar	R≤1	R>1	No R
TMM 40mbar	R≤1	R>1	No R
TMM 50mbar	R≤1	R>1	No R

TMM = tubomanometry

Tbl. 2 Tube dilatation with 2-months follow-up (115 ears monitored)

Ears	Valsalva test, pre-operative	Clicking sound when swallowing, pre-operative	Valsalva test, 2 months post-operative	Clicking sound when swallowing, 2 months post-op
Always positive	14	7	77	61
Sometimes	21	27	16	32
Negative	80	81	22	22

Tbl. 3 Tube score (50 ears completely monitored in the Friedmann test, p=0.001)

Time of measurement	Median	Standard	Min	Max	25. Percentile	50. Percentile	75. Percentile	Mean Rank
Pre-operative	1,98	2,01	0	8	1,0	3,25	0,0	1,48
1 week post-op	4,76	2,96	0	10	5,0	7,00	2,75	2,52
2 weeks post-op	6,00	2,47	1	10	6,0	8,00	4,00	3,20
2 weeks post-op	5,28	2,62	1	10	5,0	7,00	3,00	2,80

Tbl. 4 Tube dilatation with one-year follow-up (20 ears monitored)

Ears	Valsalva test, pre-operative	Clicking sound when swallowing, pre-operative	Valsalva test, 12 months post-operative	Clicking sound when swallowing, 12 months post-op
Always posit.	2	0	9	7
Sometimes	3	1	9	10
Negative	15	19	2	3

small population of – 12 patients.

After 2 months

Sixty-six patients (115 tuboplasties) were examined in a follow-up assessment 2 months after the operation. This corresponds to about 70% of the 94 patients at 2 months after dilatation of the eustachian tube. The patients were 32 women and 34 men with an average age of 54 years (18–86 years). Forty-four of these patients subjectively showed distinct improvement, 14 patients showed slight improvement, and 8 patients no improvement. Sixty-seven per cent of the patients were very satisfied with the result, which correlates well with the values objectively measured and presented below. When the tube score was measured, 22 ears (about 19%) showed only slight improvement after eustachian tube dilatation, and 24 (about 21%) of the ears treated showed no improvement. This corresponds to a distinct improvement in symptoms and findings in 60% of the ears treated, however. The ability to perform the Valsalva manoeuvre and the clicking in the ears when swallowing prior to and 2 months after the operation is presented in Tbl. 2. Pre-operatively, the tube score was 2.21 (±2.02 SD), and therefore roughly corresponds to the pre-operative tube score of 2.33 (±1.94 SD) of all patients examined so far. Two months after the operation, the tube score of the patients followed-up was 5.4 (±2.53 SD), with 90 significant improvements of the tube score (p=0.001 in the Wilcoxon test) in 115 ears treated (Tbl. 5). The evaluation of the 50 tuboplasties with complete follow-up measurements after 1 week, 2 weeks, and 2 months is shown in Tbl. 3.

After 12 months

The first 12 patients (20 tuboplasties) to be followed-up 12 months after the operation were 6 women and 6 men with an average age of 54 years (25–86 years). From 20 patients treated, 60% (12 patients) presented for follow-up at least 12 months after tuboplasty. Ten patients showed distinct improvement of the symptoms and findings, and 2 patients showed slight improvement. This corresponds to a distinct improvement of the findings in 83% of the tube dilatations, and a slight or no improvement in 17% of the patients. All patients were subjectively satisfied with the outcome. This demonstrates a clear correlation between measurable and subjective improvement. When separately considering the development of the ability to perform the Valsalva manoeuvre, the pre-operative status was negative in 15 of the 20 ears followed-up, sometimes positive in 3 ears, and always positive in 2 ears. After 12 months, the status was always positive in 9 of the 20 ears followed-up, sometimes positive in 9 ears, and for only 2 of the ears, the Valsalva manoeuvre could not be performed (Tbl. 4). Tympanograms are available for 9 of 12 patients for the time prior to the operation and for 12 months post-operatively. When evaluating the tympanograms of these 9 patients (15 ear findings), 9 tympanograms showed no changes, and 6 tympanograms showed improvement of the findings (Tbl. 5). The pre-operative tube score was 1.25 (±1.83 SD) and the value at 12 months after the operation was 6.2 (±2.61 SD), with 20 significant improvements of the tube score (p=0.001 in the Wilcoxon test) in 20 ears treated (Tbl. 6). The evaluation of the 16 tuboplasties with complete follow-up measurements after 1 week, 2 weeks, 2 months, and 1 year is shown in Tbl. 6, and the individual tube scores of all 12 patients are listed in Tbl. 7.

Impact of tuboplasty on pathological ear findings

Of the patients we have treated so far, middle ear effusion was present in 9 patients (11 ears), which could not be resolved by means of paracentesis and/or middle ear drainage. In 5 of those patients (6 ears), the effusion was no longer given during follow-up 2 months after the operation. One patient showed only slight effusion in the respective ear, and in 3 patients (4 ears) the effusion had not changed so that we decided to perform paracentesis and middle ear drainage. With this very small patient population, the middle ear effusion was no longer detectable after tuboplasty in 50% of the cases.

Tbl. 5 Tympanogram at the one-year follow-up (15 ears monitored)

Ears	Delta C, pre-op (ml)	P, pre-op (daPa)	Delta C, 12 months post-op (ml)	P, 12 months post-op (daPa)
1	0,91	–222	0,23	–121
2	0,83	–204	0,31	–94
3	0,12	–265	0,05	–104
4	0,36	0,12	0,24	–292
5	0,29	–141	0,12	–263
6	0,17	–154	0,34	–133
7	0,10	–254	0,1	–60
8	0,26	–150	0,27	–38
9	0,72	–34	0,85	–42
10	1,8	–23	2,53	–18
11	0,2	–96	0,92	10
12	0,37	–152	0,24	–126
13	0,07	139	0,16	–161
14	0,05	–17	0,66	–42
15	0,54	–154	0,37	–227

Tbl. 6 Tube score (16 ears completely monitored in the Friedmann test, p=0.001)

Time of measurement	Median	Standard	Minimum	Maximum	25th percentile	50th percentile	75th percentile	Mean rank
Pre-operative	1.19	1.76	0	6	0.5	1.75	0.0	1.44
1 week post-operative	3.63	3.24	0	10	3.5	6.75	0.0	2.63
2 weeks post-operative	5.44	2.25	2	9	5.0	7.75	3.25	3.44
2 months post-operative	5.69	2.09	2	10	6.0	7.0	4.00	3.75
1 year	5.63	2.58	2	10	5.4	8.5	3.25	3.75

Tbl. 7 Tube score of the 12 patients with follow-up after one year

Pre-operative		1 week	2 weeks	2 months	12 months
1	r 1, l 6	r 4, l 6	r 9, l 5	r 10, l 6	r 9, l 9
2	l 1	l 8	l 6	l 6	l 7
3	r 0, l 0	r 0, l 3	r 7, l 5	r 7, l 7	r 3, l 4
4	r 0, l 0	r 7, l 7	r 8, l 8	r 6, l 7	r 5, l 5
5	r 0, l 0	r 0, l 0	r 3, l 3	r 4, l 5	r 2, l 3
6	r 0, l 1	r 4, l 10	r 2, l 6	r 3, l 9	r 3, l 9
7	r 4	r 4	r 9	r 6	r 10

In 2 cases, which were patients without middle ear effusion, a reduction of the pre-operatively documented sound conduction by up to 20dB in at least 3 frequencies was determined.
In 9 of the patients in which a follow-up assessment was performed at least 2 months after tuboplasty, 10 ears showed pathological findings at the tympanic membranes which were simply monitored subsequently and not subjected to specific treatment. A small tympanic membrane perforation known to exist for at least one year was present in 3 patients. That perforation had been closed in 2 ears at the follow-up assessment performed 2 months after the eustachian tube dilatation. Retraction of the tympanic membrane was visible in 7 ears prior to the operation, and was detected to persist in 4 ears only at 2 months after tuboplasty. The patient population examined was again very small, but a positive impact of tuboplasty on the ventilation of the middle ear and subsequent improvement of tympanic membrane retraction without cholesteatoma and small tympanic membrane perforations has been demonstrated.

Combination of tuboplasty with operations at the ears and nose

In 6 patients, we performed tuboplasty in combination with surgery at the paranasal sinuses, the septum and/or the inferior conchae. The pre-operative tube score in this group was 2.45 (±2.5 SD), and 4.64 (±3.41 SD) at 2 months post-operatively.
In 8 patients, tuboplasty was combined with tympanoplasty or a revision of a previous tympanoplasty in order to improve ventilation of the middle ear as well as the surgical outcome. In this subgroup, the pre-operative tube score was 2.85 (±2.76 SD), and 5.15 (±2.64 SD) at 2 months post-operatively.

Discussion

A variety of therapeutical approaches and concepts for treating chronic obstructive eustachian tube dysfunction have been examined. Presently, new publications mainly refer to endonasal dilatation of the eustachian tube using a balloon catheter and laser tuboplasty as surgical procedures. Caffier et al and Poe et al primarily report on the results of laser tuboplasty.[1, 18] The first long-term results by Caffier et al show an improvement of the eustachian tube function after 8 weeks in 62% of the patients, and after 1 year in 66%. Further long-term results regarding e.g. scarring and a tendency to develop restenosis after laser therapy of the mucosa have to be awaited. Our clinic works on a minimally invasive procedure for treating chronic obstructive ventilation disorders of the eustachian tube – balloon dilatation eustachian tuboplasty using the Bielefeld balloon catheter. In February 2009, we performed the first eustachian tube dilatation using the Bielefeld balloon catheter, and had treated 120 patients using this method until August 2011. Presently, the number of patients we have treated is still relatively small, but it allows for initial statistical evaluations.
Several papers from our clinic on the fundamentals of balloon dilatation eustachian tuboplasty using the Bielefeld balloon catheter including feasibility studies are available.[13, 14, 15] The mechanism on which eustachian tube dilatation is based has not been finally established yet, but our preliminary examinations indicate that eustachian tube dilatation leads to micro-fractures within the cartilage of the tuba auditiva and persistent extension of the so-called Rüdinger safety canal. Moreover, post-inflammation adhesions in the cartilaginous part of the eustachian tube may be dissolved. In particular, middle ear effusion and eustachian tube dysfunction have been reported frequently in patients who had received radiation treatment in the area of the eustachian tube.[25, 11] The cause may be assumed to be mainly scarring in the cartilaginous membrane part of the eustachian

tube.[8, 22]. Further examinations regarding treatment options using eustachian tube dilatation seem to be worthwhile.

Indications

As described above, our examination of the initial long-term results of balloon dilatation eustachian tuboplasty showed a significant improvement of the findings in 90% of the tube dilatations after at least 12 months. Here, it should be noted that our examination has spanned a relatively small number of patients so far, and that the first results regarding sustainability of this therapy in form of control results at 24 months after surgery are not available yet. Nevertheless, our results indicate a subjectively high satisfaction of the patients with the surgical outcome together with an also objectively better eustachian tube function. The exact mechanism tube dilatation is based on can only be speculated upon. Especially important for successful therapy of chronic obstructive eustachian tube dysfunction appears to be the exact and ascertained indication. This indication may be difficult to determine since in the scope of the preliminary examinations and recording of the medical history, correlating results from tympanometry and TMM may be lacking. In our opinion, a hard indication is when the Valsalva manoevre can repeatedly not be performed, tube aperture is missing in TMM, and the typical symptoms are given. While we initially treated only such patients using tube dilatation who fulfilled those criteria, last year we began to treat also patients with a tube score up to 5, and sometimes also patients with an even higher tube score but with recurrent middle ear effusion (after exluding other causes) or recurrent adhesive processes. With the first 20 patients in particular, we followed a very strict indication for surgery (pre-operative tube score of 1.25). Since we have been including also patients with a tube score of up to 5, inability to perform the Valsalva manoeuvre and typical symptoms, the pre-operative tube score is about 2.3 on an average. A particular problem poses the group of patients with strong but partly indistinct symptoms and only few objectively measurable correlating findings, such as patients with neurotic symptoms at the eustachian tube. Here, we recommend the patients to get comprehensive consulting regarding tube dilatation and the realistic therapeutic options associated with it; as a rule, we offer this procedure to such patients only, if their tube score is under 5. In addition, it should be noted that, due to ethical concerns, there are no double-blind randomised studies evaluating the effect of tube dilatation compared to a control group, and that this procedure has been applied for 3 years only. Its efficacy has not been objectively established yet, but our data and examinations by 22 other clinics in Germany seem to prove a benefit for many patients.

Other authors have independently examined the possibility of endonasal dilatation of the eustachian tube as well.[19] Poe et al in particular published a study on the treatment of chronic obstructive eustachian tube dysfunction using an independently developed balloon catheter in 2011.[20] In 2009, they dilated the cartilaginous part of the tuba auditiva for 1 minute using 12atm (12.2bar) in 11 patients. With a diametre of 7mm and a length of 16mm, the catheter they used is slightly shorter and thicker than ours. The essential indicative criteria during preliminary examinations were the inability to perform the Valsalva manoeuvre, and no tube opening when swallowing. As reported by the research group, there have been no post-operative complications, and all patients were able to perform the Valsalva manoeuvre after the operation. The patient population examined by Poe et al was distinctly smaller than ours, but the total results are similar. Presently, it is not possible yet to define a standard regarding the size of the balloon, the application of pressure, and the duration of the application. While we have been able to present good results with minimum complications using the Bielefeld concept of eustachian tube dilatation, further tests for optimising the procedure with regard to the catheter, endoscope, or dilatation time are being conducted. Presently it seems to make more sense, however, to consider a longer dilatation time instead of increasing the catheter thickness due to the potentially higher risk for complications. The comparison of our data with the pending comprehensive long-term data by Poe et al will remain informative.

Medicinal therapies of eustachian tube dysfunction with nasal drops containing cortisone and/or decongestant nasal drops have been discussed as well, they have not yielded any significant improvement of tube function in scientific studies so far, however. Gluth et al published a prospective, randomised and placebo controlled study on the impact of nasally applied steroids on eustachian tube function. The results did not indicate any statistically significant difference between the active substance and placebo in their impact on eustachian tube function and otitis media.[7] Thus, the investigations of Gluth et al confirm that our post-operative results have been attributable to the eustachian tube dilatation and not to the topinasal add-on therapy. We prescribe the nasal spray containing cortisone after the operation in order to achieve a reduction of the local swelling after surgery and reduce potential scarring tendencies at the nasopharyngeal fold.

Reliable and reproducible measurement of the eustachian tube function is decisive for being able to determine the indication for tube dilatation and to evaluate the success of tuboplasty.

The TMM acc. to Estève appears to be a simple, cost efficient and feasible procedure to assess the function of the eustachian tube. It can be applied in practice without any problems and offers good options to demonstrate the tube function both with intact and with perforated tympanic membranes.[5, 6] This is a decisive advantage compared to other procedures such as tympanometry, which can be performed with an intact tympanic membrane only, or e.g. the inflation-deflation test in case of a perforated tympanic membrane. While other techniques such as tests in the pressure chamber can deliver good results regarding the eustachian tube function, they are associated with high organisational and technical efforts and costs and are thus rather not useful for daily practice.[9] In his current paper on the eustachian tube and the middle ear mechanics, Pau also describes the persisting problems when examining the tube function and discusses the different procedures as well as new diagnostic approaches.[16] A normal tympanogram on the day of outpatient presentation at our clinic and/or prior to the operation in particular does not exclude dysfunction of the eustachian tube in our view. It always has to be evaluated in the context of the tympanic membrane findings. In unclear cases, the tympanogram should always be considered for assessment of the tube function. For this reason, we try to establish the TMM and the tube score as aids for determining an indication. At present, we are examining the reliability and validity of the tube score in a large number of patients in the scope of another study. The tube score is determined

using the TMM acc. to Estève, and in our opinion, we are in the course of further establishing a good diagnostic instrument for evaluating the eustachian tube function. We intensively use the TMM for assessing the therapeutic success of tuboplasty. Independent of the normal values, which still have to be further examined, this procedure offers an objective possibility for intra-individual comparability of the eustachian tube function in individual patients over time. It is also an essential goal of eustachian tube dilatation to achieve subjective symptom improvement for the patients. For this reason, we deliberately take into account the subjective criteria of the patient's ability to perform the Valsalva manoeuvre and the clicking when swallowing in the calculation of the tube score. It certainly should be considered to enhance this tube score by the criterium of objective ability to perform the Valsalva manoeuvre and the tympanometric results. Like with the TMM, the results can only represent a current snapshot of the state at the time of examination, while we are particularly interested in noticeable improvements in the daily life of the patient. The ability to perform the Valsalva manoeuvre in particular is often negative prior to the TMM and positive afterwards, so that it does not appear to be a stable evaluation criterion either. Basically, we still need a better method to assess the results of eustachian tube dilatation, which we continue to work on.

Combination with other surgical procedures

Considering the current data indicating a slightly less positive post-operative outcome when eustachian tube dilatation is combined with another operation at the nose and paranasal sinuses, we recommend to carry out surgical repair of the nose and paranasal sinuses first, and perform tuboplasty 2 months after the initial surgery, if the obstructive eustachian tube dysfunction persists.

With chronic obstructive eustachian tube dysfunction and simultaneous indication for tympanoplasty or tympanoplasty revision, we recommend, based on our data and previous experience, to perform eustachian tube dilatation about 2 months prior to the tympanoplasty. The objective here is to optimise eustachian tube function in order to achieve a better prognosis for the tympanoplasty. Further investigations regarding the impact of eustachian tube dilatation on the outcome of tympanoplasties are being conducted.

Conclusions for the daily practice

- The initial long-term results of balloon dilatation of the eustachian tube have demonstrated that this method is a feasible and safe therapeutic procedure with only few side effects.
- The initial long-term results indicate a possibility to improve the eustachian tube function in case of chronic obstructive eustachian tube ventilation disorders.
- Further multi-centric studies evaluating the results of eustachian tube dilatation using the Bielefeld balloon catheter as well as possible risks and complications of this therapy and the combination of eustachian tube dilatation with tympanoplasties will be conducted starting in 2012.

Contact address for correspondence

Dr. S. Schröder
Klinik für Hals-Nasen-Ohrenheilkunde, Kopf- und Halschirurgie
Klinikum Bielefeld
Teutoburger Str. 50
33604 Bielefeld
stefanie.schroeder@klinikumbielefeld.de

Conflict of interests. The corresponding author declares that there is no conflict of interests as far as she is concerned. M. Lehmann, J. Ebmeyer, and H. Sudhoff receive fees for lecture services as well as financial allowances for research projects.

Literature

1. Caffier PP, Sedlmaier B, Haupt H et al (2011) Impact of laser eustachian tuboplasty on middle ear ventilation, hearing, and tinnitus in chronic tube dysfunction. Ear Hear 32(1):132–139
2. Choi SH, Han JH, Chung JW (2009) Preoperativeevaluation of eustachian tube function using a modified pres sure equilibration test is predictive of good postoperative hearing and middle ear aeration in Typ1 tympanoplasty patients. Clin Exp Otorhinolaryngology 2(2):61–65
3. Di Martino E, Krombach GA, Thaden R, Westhofen M (2004) Function tests for the eustachian tube. Current knowledge. HNO 52(11):1029–1040
4. Dörrie A, Dommrich S, Pau HW (2003) Early postoperative middle-ear ventilation – risk for the transplant or guarantee for aeration of the tympanic cavity? Laryngorhinootologie 82(2):102–104
5. Esteve D (2003) Tubomanometry and pathology. In: Ars B (Hrsg) Fibrocartilaginous eustachian tube. Middle ear cleft. S 159–175
6. Esteve D, Della Vedova C, Dubreuil C et al (2001) Evaluation par tubomanometrie de la fonction douverture tubaire et de la ré ponse tympanique chez le sujet normal et chez le sujet porteur dune otide séromuqueuse chronique. J Fr ORL 50:223–231
HNO 9 2012 |
7. Gluth MB, McDonald DR, Weaver AL et al (2011) Management of eustachian tube dysfunction with nasal steroid spray: a pros pective, randomized, placebo-controlled trial. Arch Otolaryngol Head Neck Surg 137(5):449–455
8. Hsu MM, Young YH, Lin KL (1995) Eustachian tube function of patients with nasopharyngeal carcinoma. Ann Otol Rhinol Laryngol 104(6):453–455
9. Leuwer R, Koch U (1999) Anatomy and physiology of the auditory tube. Therapeutic possibilities in chronic disorders of tubal function. HNO 47(5):514–523
10. Lükens A, Dimartino E, Günther RW, Krombach GA (2011) Functional MR imaging of the eustachian tube in patients with clinically proven dysfunction: correlation with lesions detected on MR images. Eur Radiol. (E-Pub)
11. Maier W, Beck C, Hinkelbein W, Richter B (1994) Effects of therapy of laryngeal and hypopharyngeal cancers on eustachian tube function. Laryngorhinootologie 73(3):164–168
12. McCoul ED, Lucente FE, Anand VK (2011) Evolution of eustachian tube surgery. Laryngoscope 121(3):661–666
13. Ockermann T (2009) Die Ballondilatation der Eustachischen Röhre zur Behandlung der obstruktiven Tubendysfunktion. Dissertationsschrift Ruhr-Universität Bochum
14. Ockermann T, Reineke U, Upile T et al (2010) Baloondilatation eustachian tuboplasty: a feasibility study. Otol Neurotol 31(7):1100–1103
15. Ockermann T, Reineke U, Upile T et al (2010) Baloondilatation eustachian tuboplasty: a clinical study. Laryngoscope 120(7):1411–1416
16. Pau HW (2011) Eustachian tube and middle ear mechanics. HNO 59(10):953–963
17. Podoshin L, Fradis M, Malatskey S, Ben-David J (1996) Tympanoplasty in adults: a five-year survey. Ear Nose Throat J 75(3):149–152, 155–156
18. Poe DS, Grimmer JF, Metson R (2007) Laser eustachian tuboplasty: two-year results. Laryngoscope 117(2):231–237
19. Poe DS, Hanna BM (2011) Balloon dilation of the cartilaginous portion of the eustachian tube: initial safety and feasibility analysis in a cadaver model. Am J Otolaryngol 32(2):115–123
20. Poe DS, Silvola J, Pyykkö I (2011) Balloon dilation of the cartilaginous eustachian tube. Otolaryngol Head Neck Surg 144(4):563–569
21. Sudhoff H, Ockermann T, Mikolajczyk R et al (2009) Clinical and experimental considerations for evaluation of eustachian tube physiology. HNO 57(5):428–435
22. Takasaki K, Hirsch BE, Sando I (2000) Histopathologic study of the human eustachian tube and its surrounding struc tures following irradiation for carcinoma of the oropharynx. Arch Otolaryngol Head Neck Surg 126(4):543–546
23. Todd NW (2000) There are no accurate tests for eustachian tube function. Arch Otolaryngol Head Neck Surg 126(8):1041–1042
24. Uzun C, Cavé-Thomasen P, Andersen J, Tos M (2004) Eustachian tube patency and function in tympanoplasty with cartilage pali sades or fascia after cholesteatoma surgery. Otol Neurotol 25(6):864–872
25. Xiao J, Luo ZQ, Shi DZ et al (2008) Short-term results of audiological change of nasopharyngeal carcinoma pa tient after radiotherapy and chemotherapy. Zhonghua Er Bi Yan Hou Tou Jing Wai Ke Za Zhi 43(12):906–909